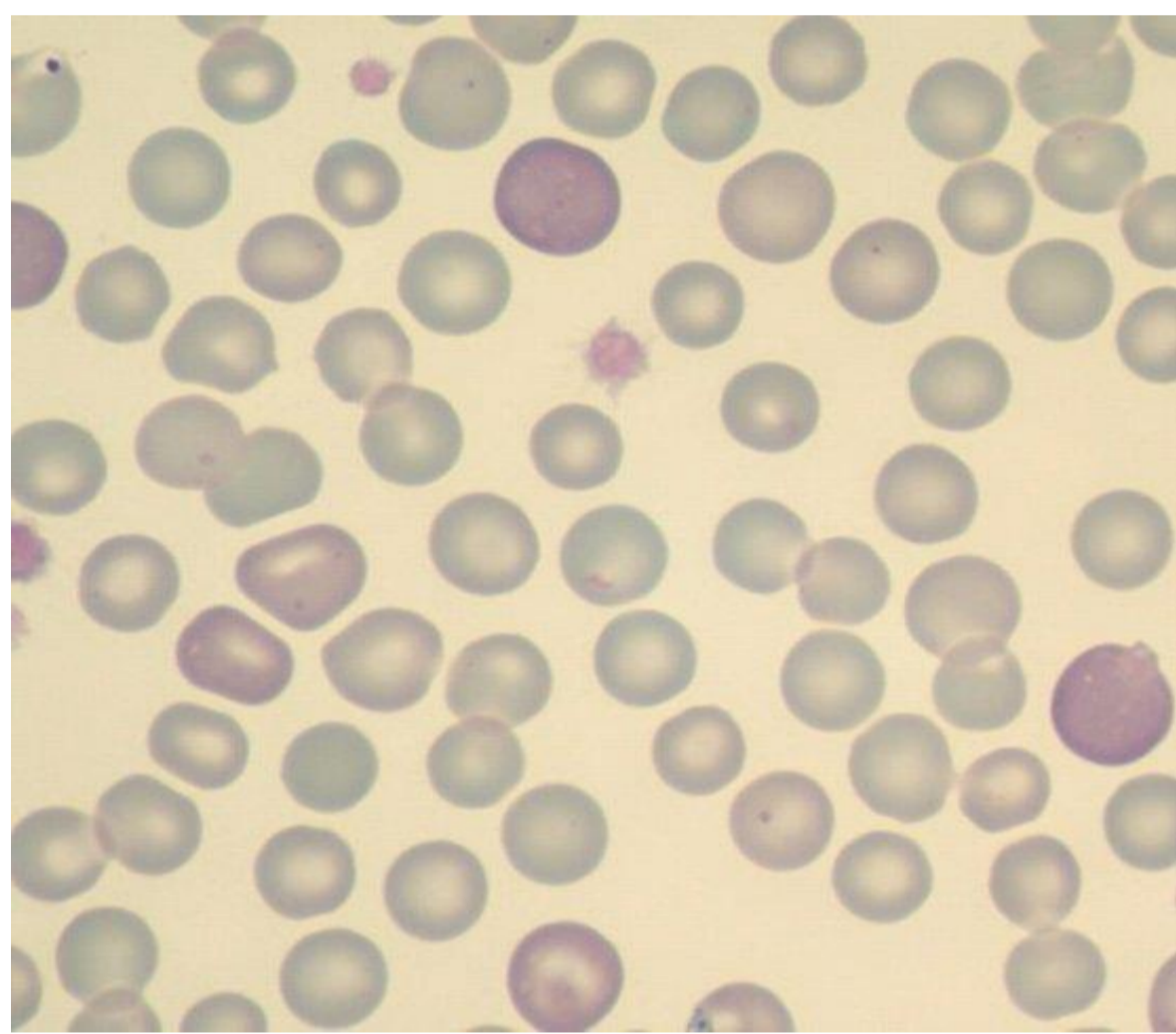


Regenerativ anemi

- Orsakas av akut blödning eller hemolytisk anemi
- Benmärgen släpper ut retikulocyter (omogna erythrocyter) i blodet

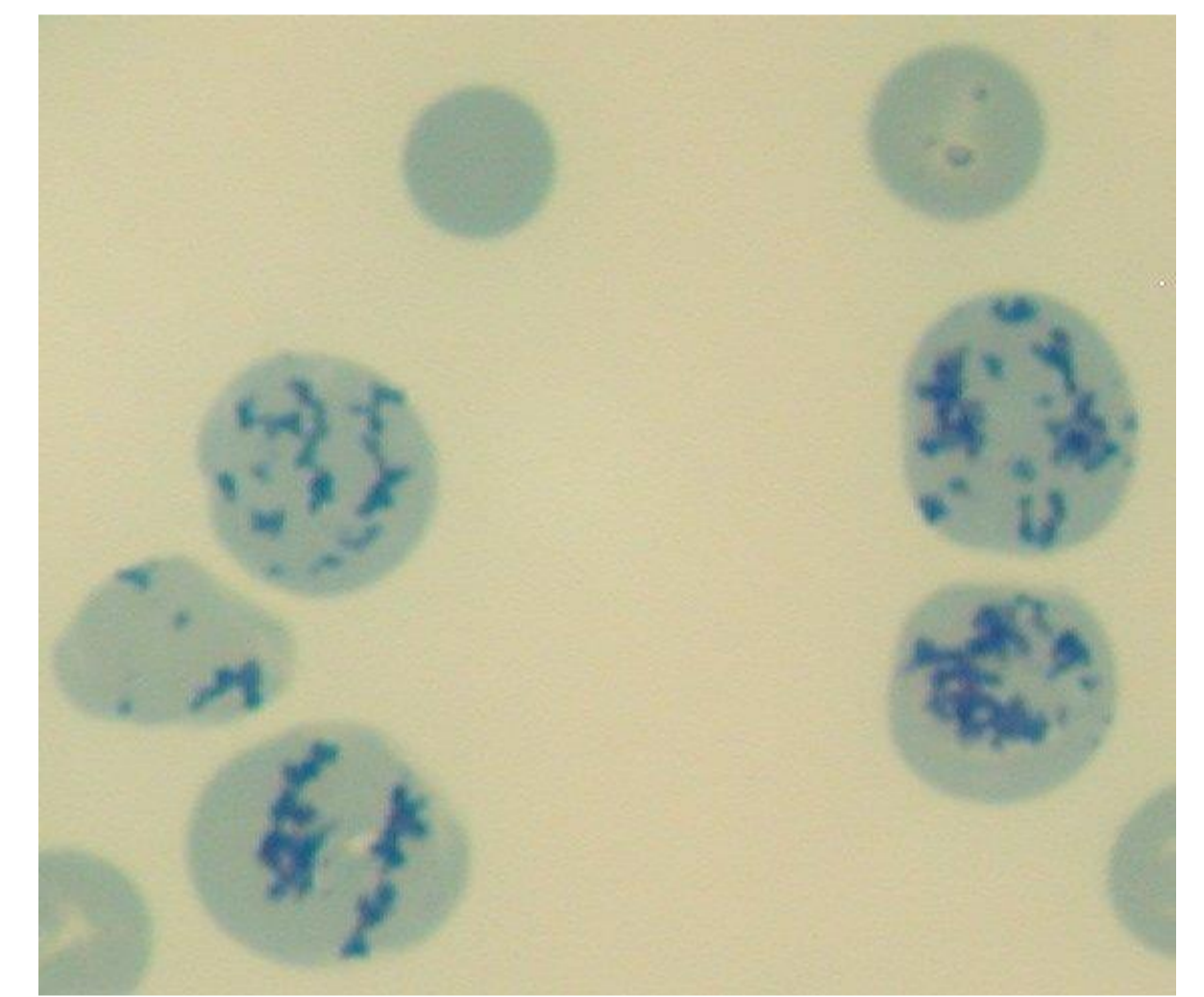
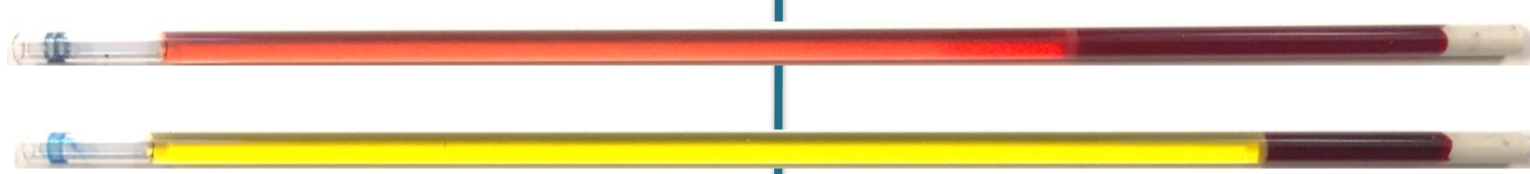

Polykromasi och anisocytos
(May-Grünwald Giemsa)

Akut blödning

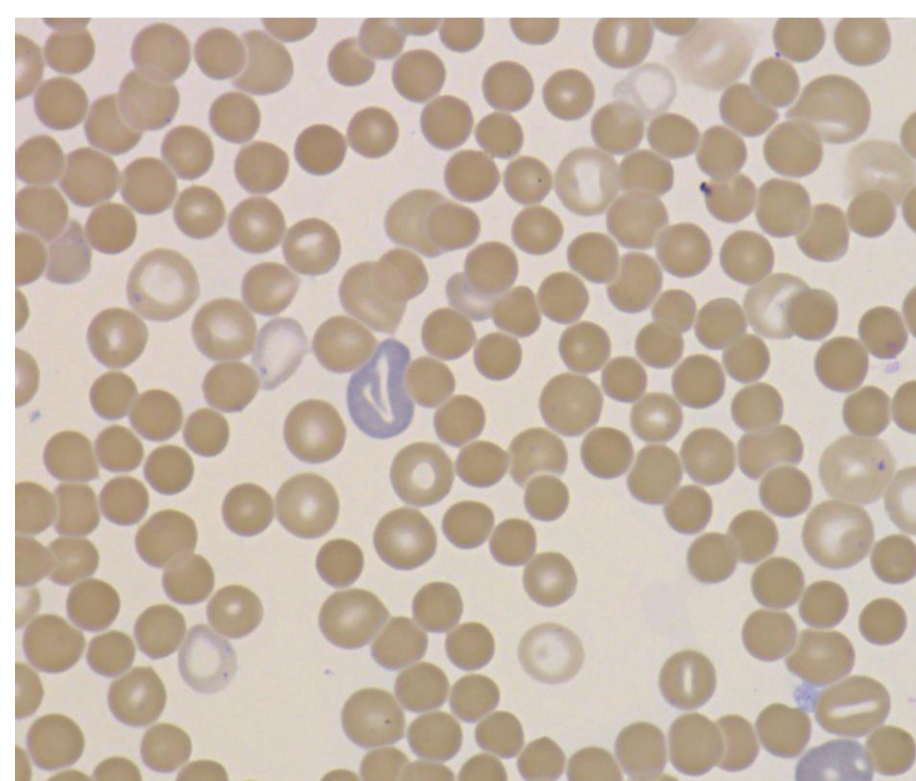


Hemolytisk anemi

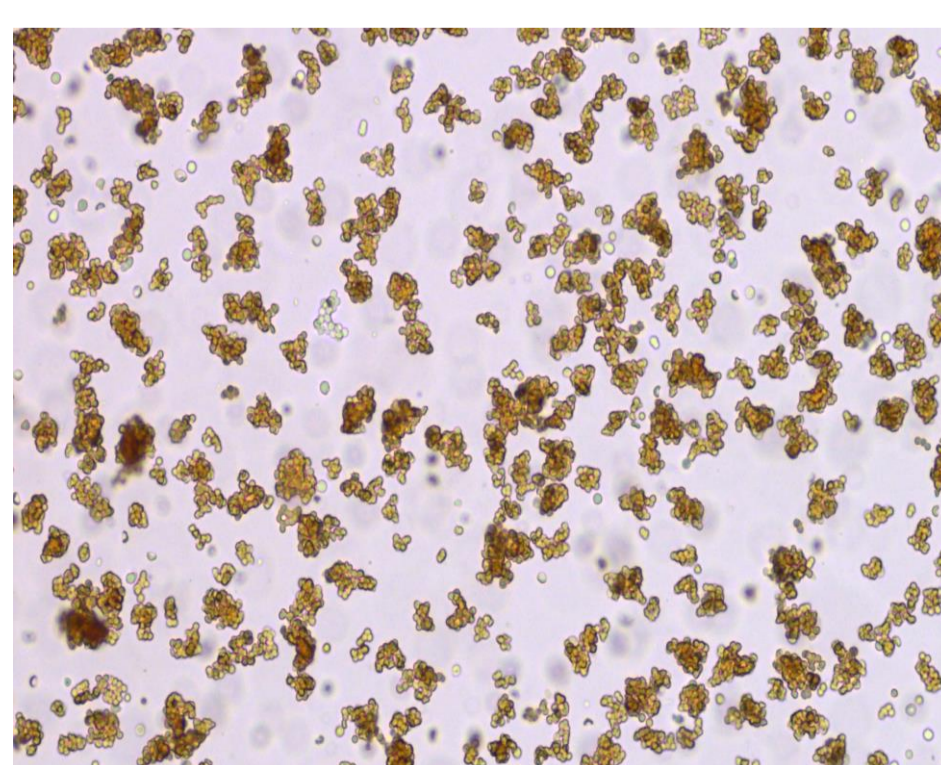


Retikulocyter
(retikulocytfärgning)

Immunmedierad hemolytisk anemi (IMHA)

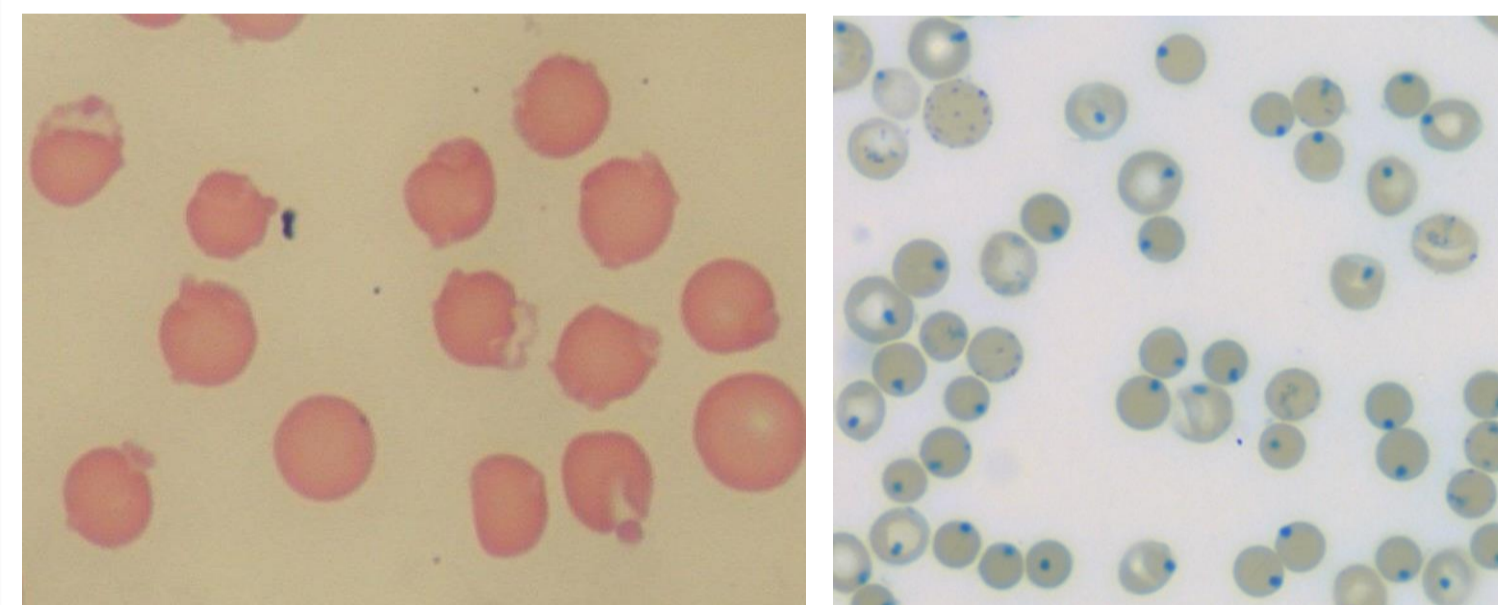


Sfärocyter



Spontanagglutination

Oxidativa skador



Retikulocytfärgning

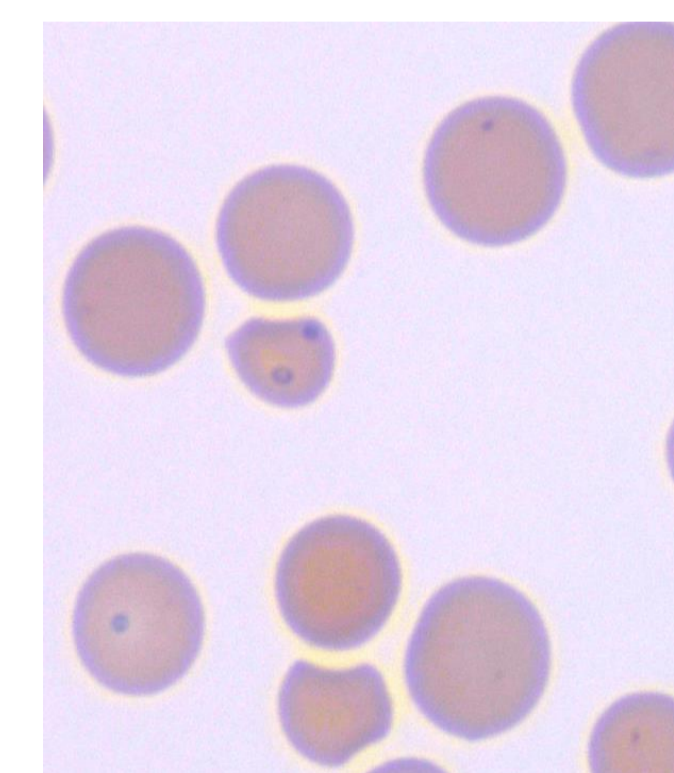
Heinzkroppar och
eccentricocyter



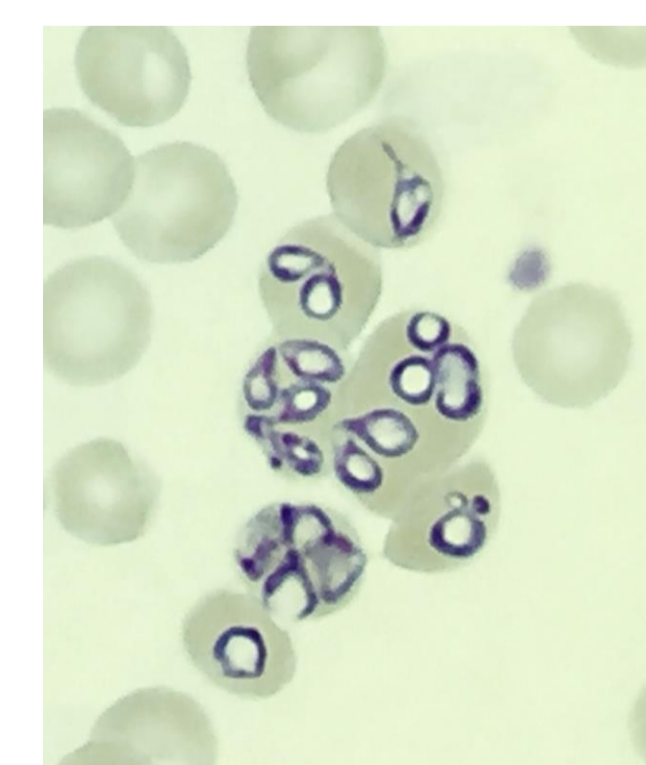
Normalt blod

Methemoglobinemi

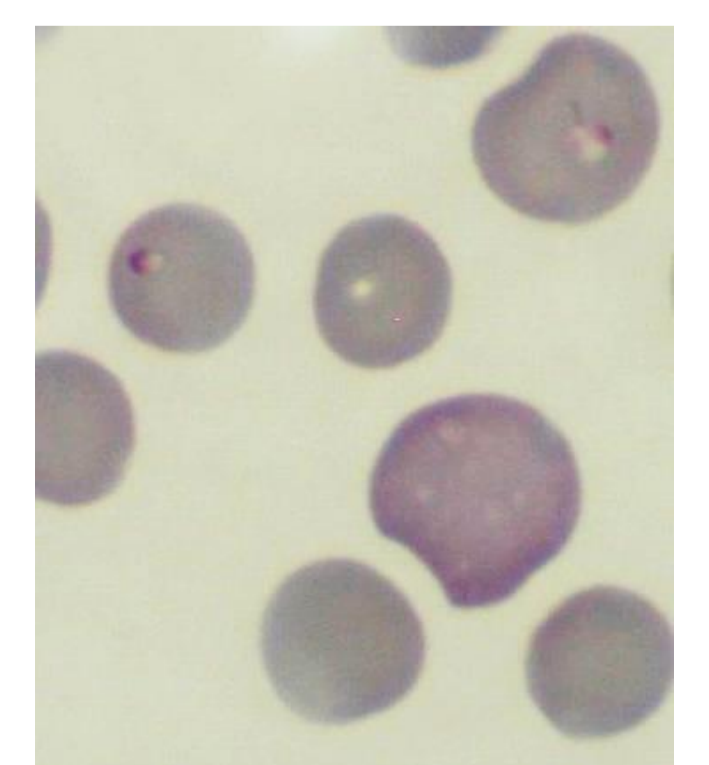
Infektioner



Mycoplasma hemofelis



Babesia
canis



Babesia
gibsoni